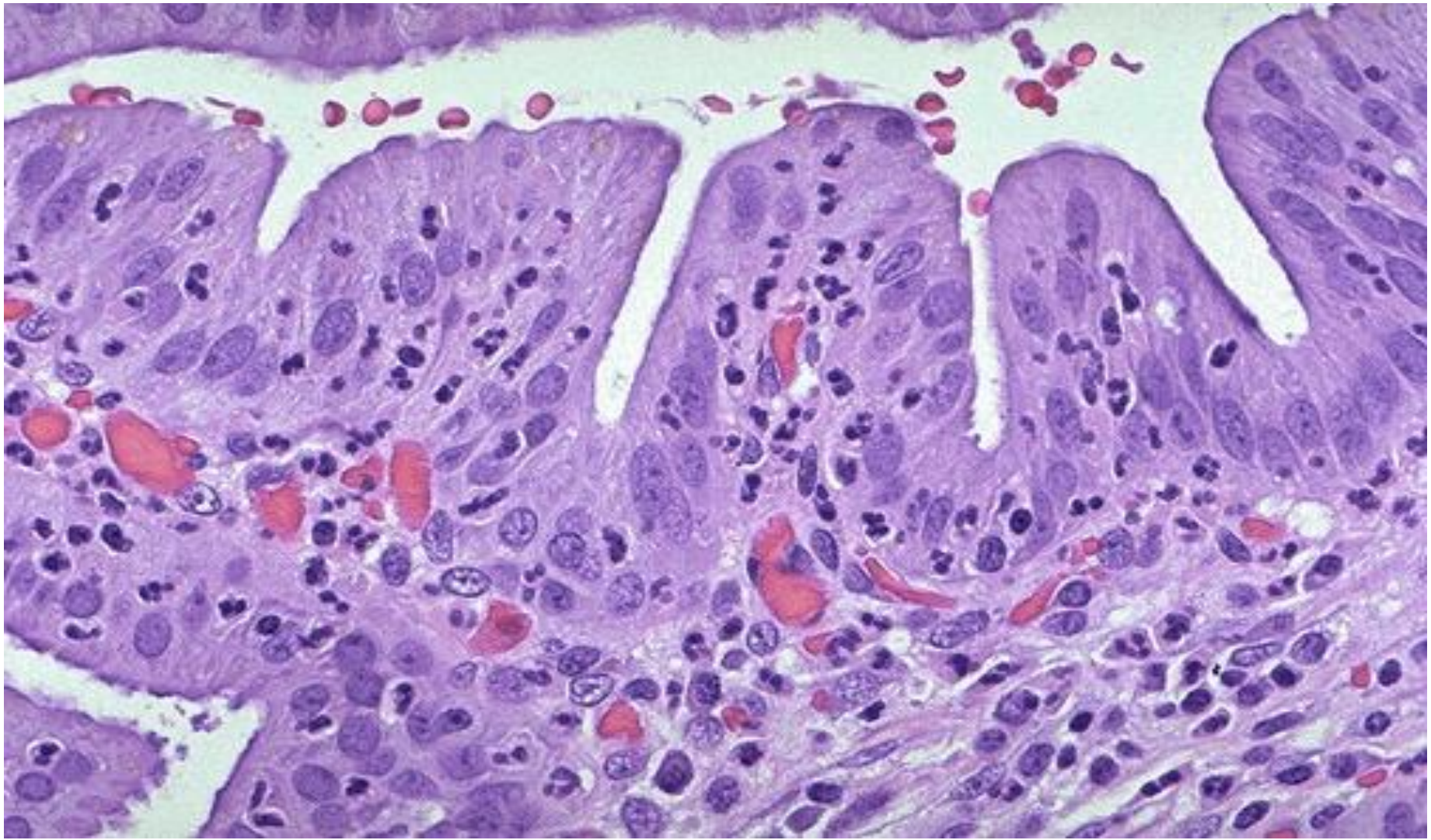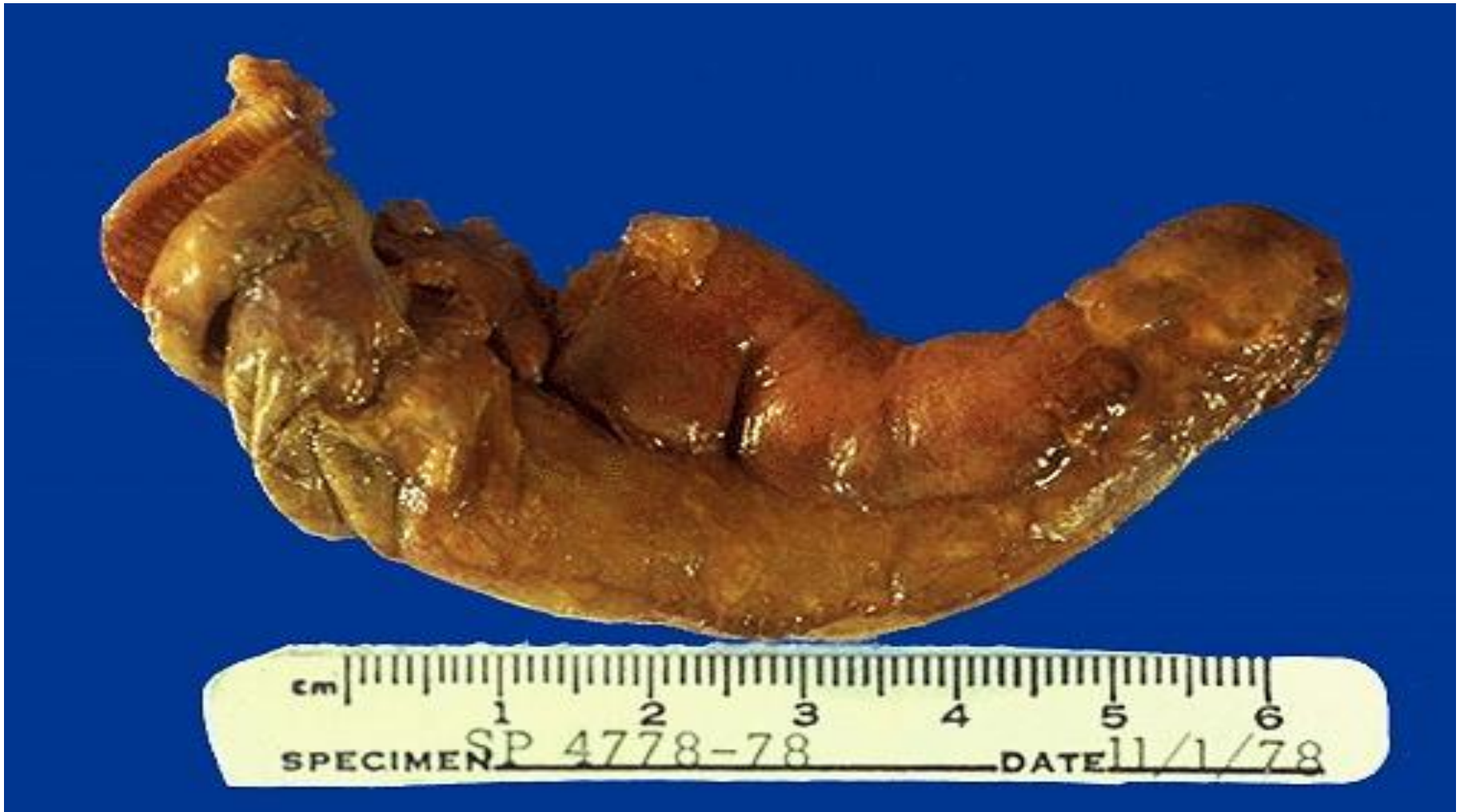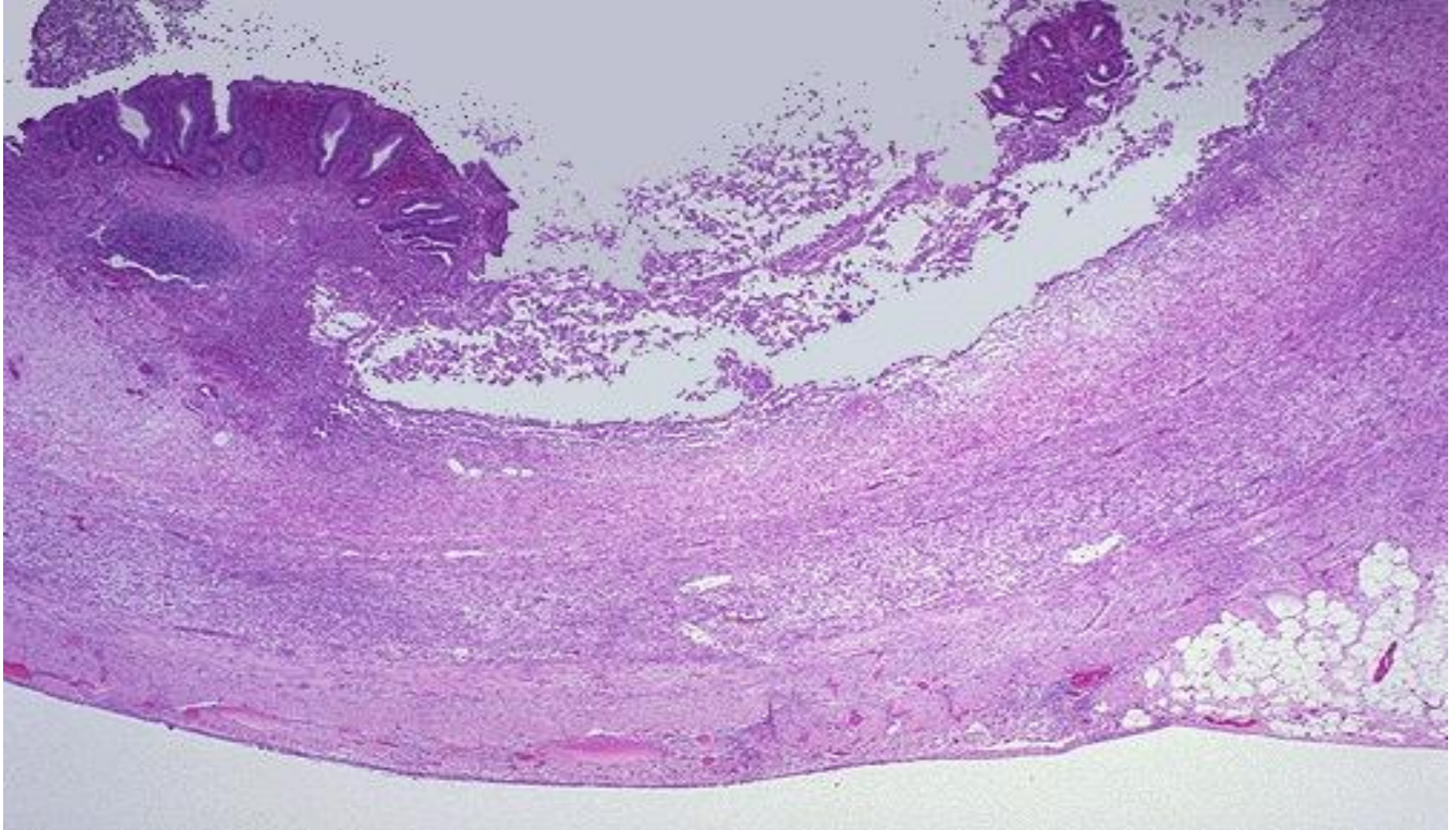


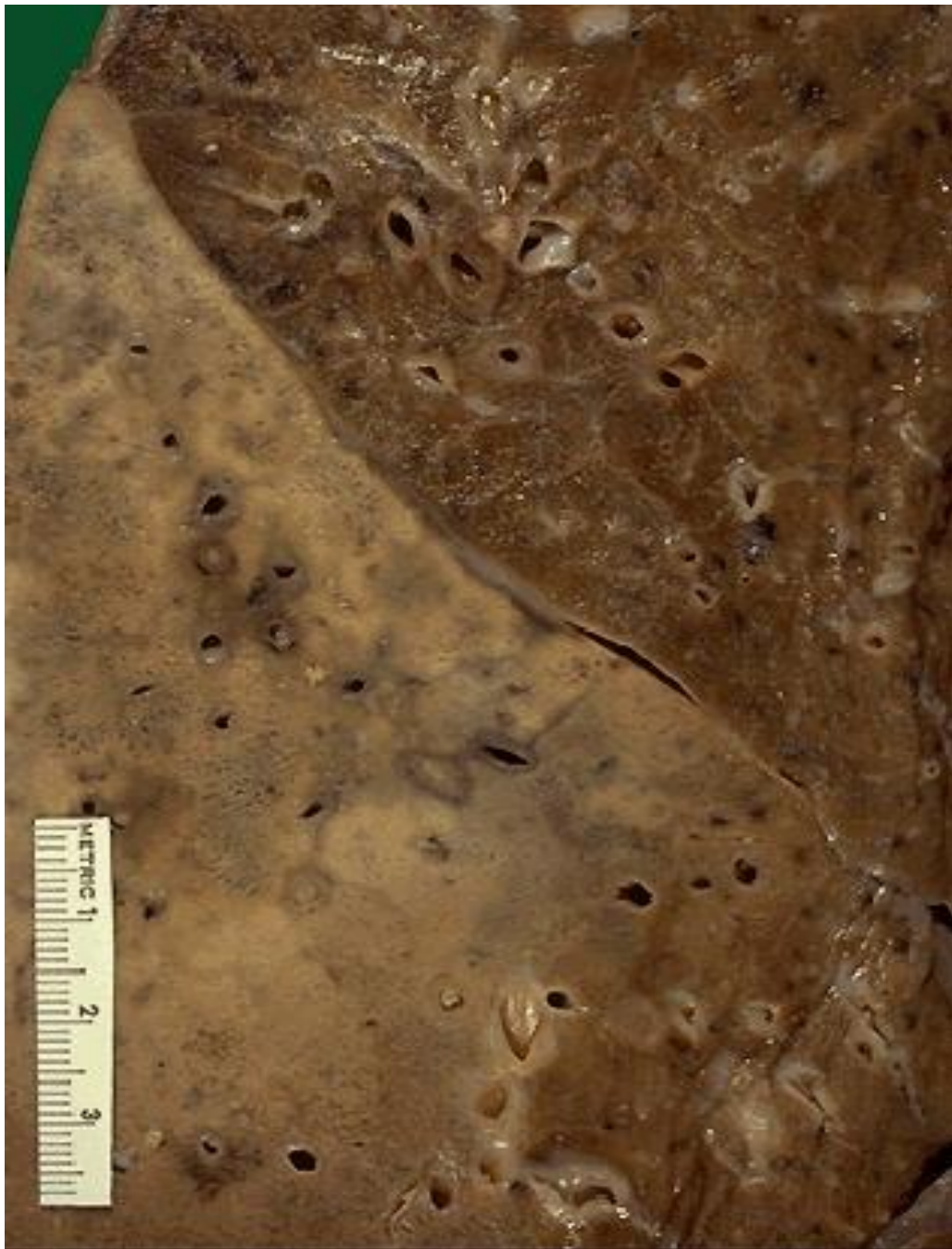
- acute cholecystitis



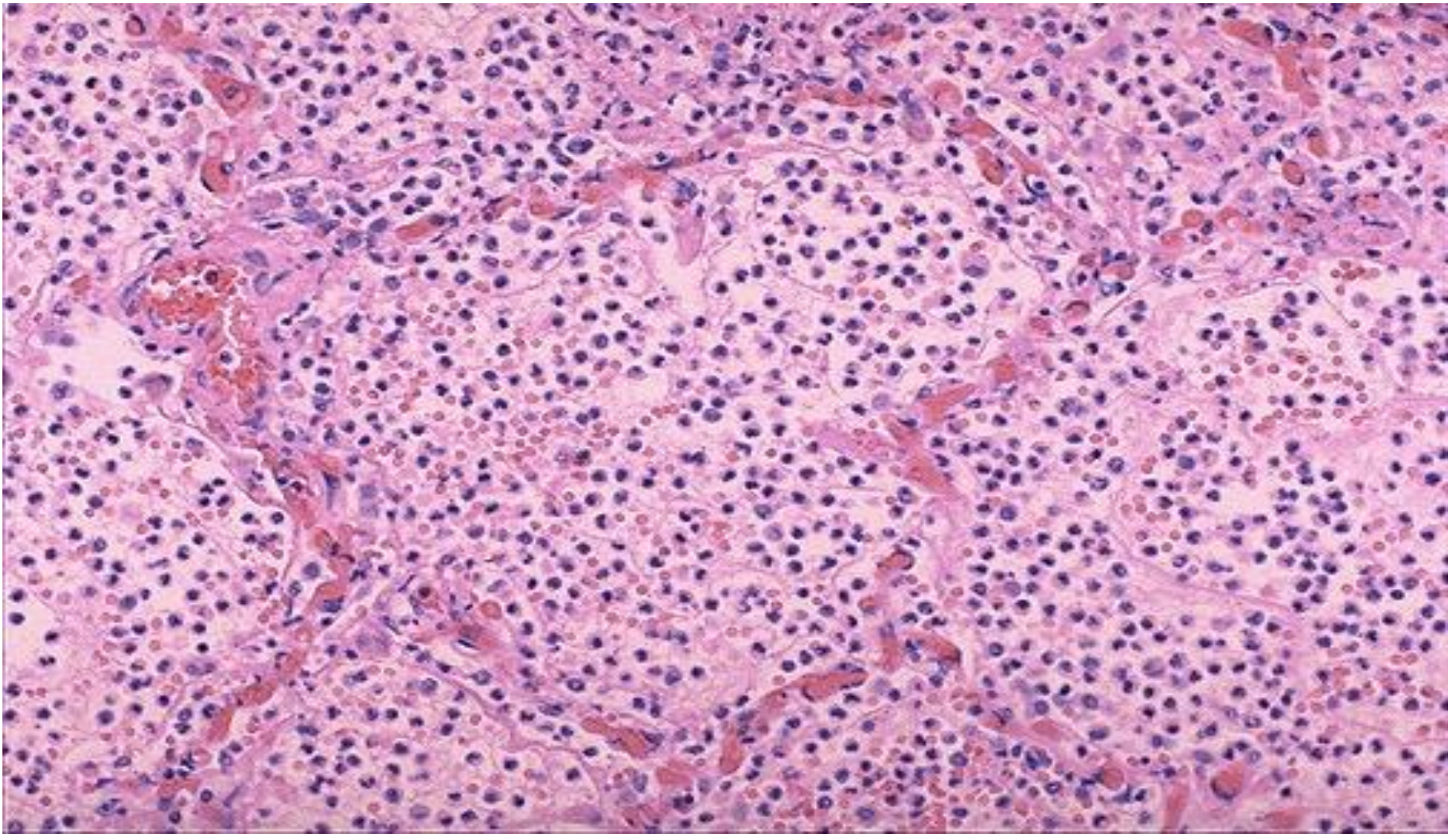
- acute appendicitis



- Microscopically, acute appendicitis .



- lobar pneumonia grossly.



- lobar pneumonia microscopically.