




- **Epigastric hernia**
- 
- **Incisional**
- 
- **Burst abdomen**
- 



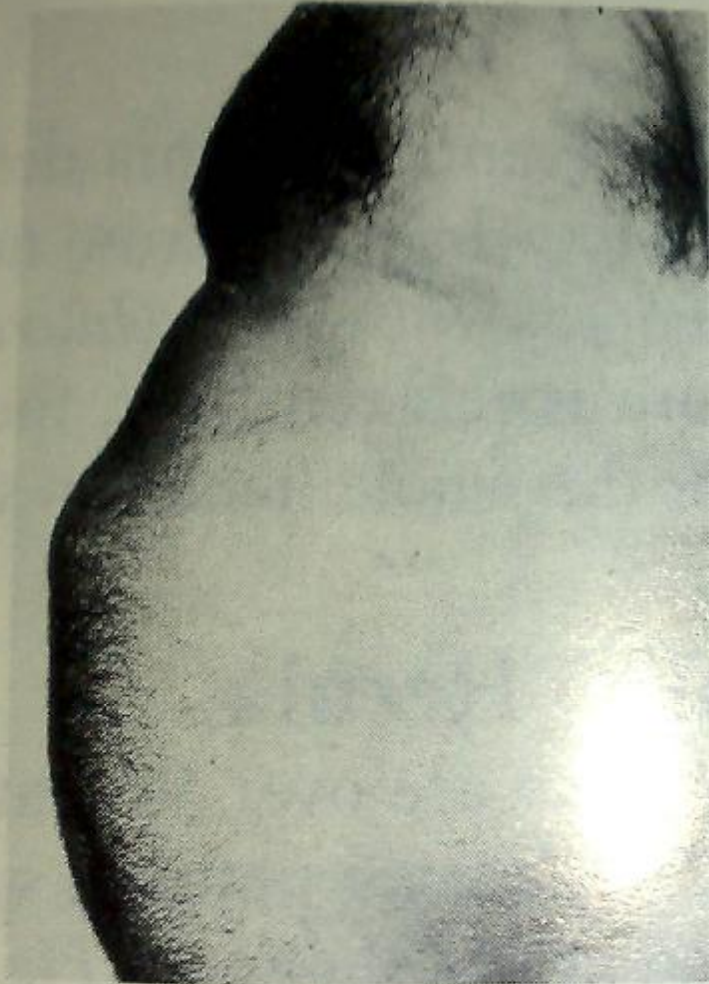


# Epigastric hernia

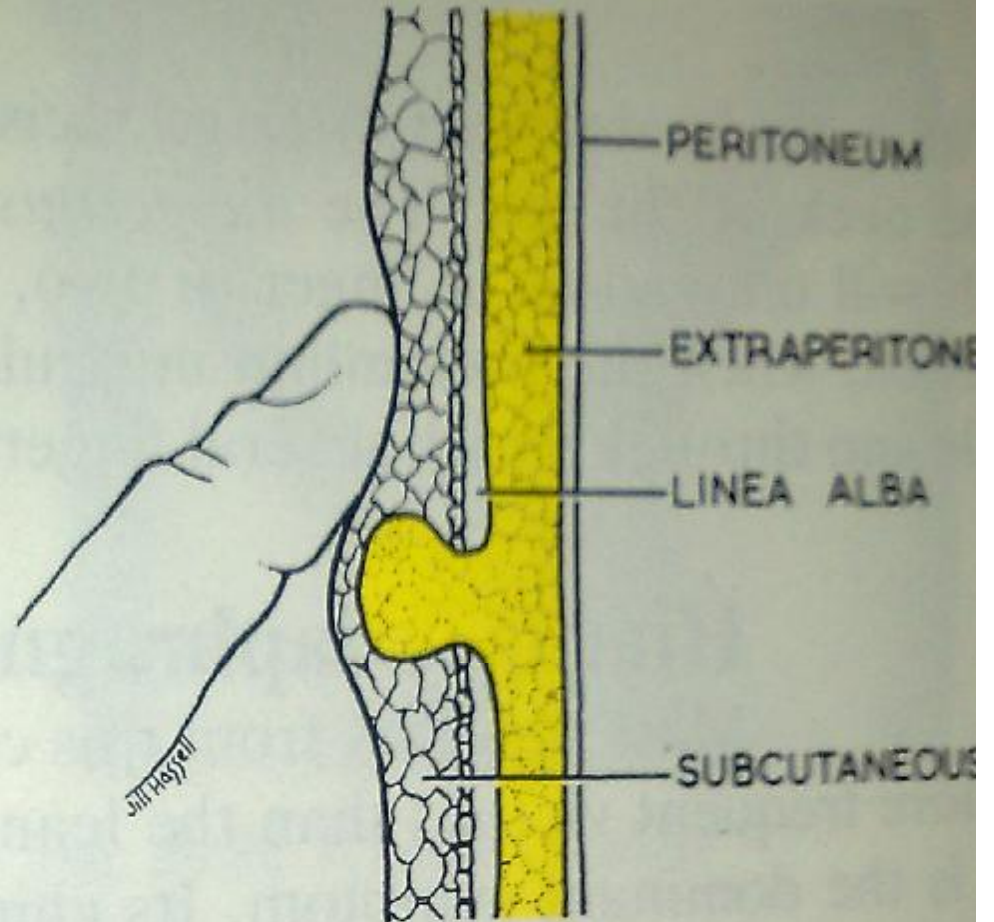
---

- n Hernial defect in the linea alba from xiphisternum to the umbilicus
- n Felt as swelling
- n My be associate with pain
- n Epigastric pain like that of DU
- n Treatment ;operative repair for painful and big one

light.



**Fig. 20.17** Epigastric hernia visible only when the patient was examined standing up. He complained of symptoms



**Fig. 20.18** Method of seeking a small epigastric hernia.

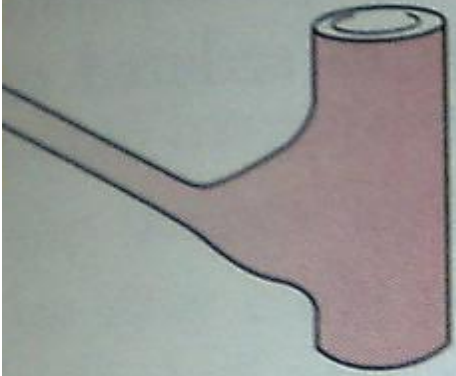
# Umbilical pilonidal sinus

- Is sinus contain hair
- Discharging pus
- Treatment ;excision

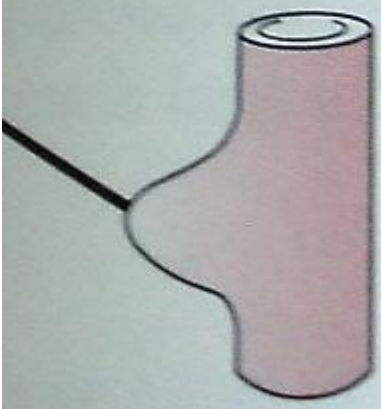
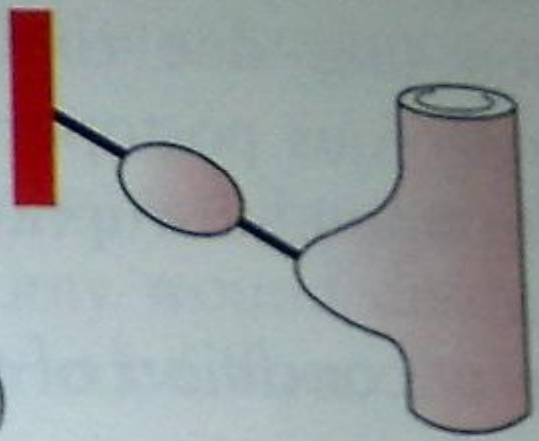
# Umbilical fistulae

- | Patent vitelointestinal duct
- | Patent Urachus

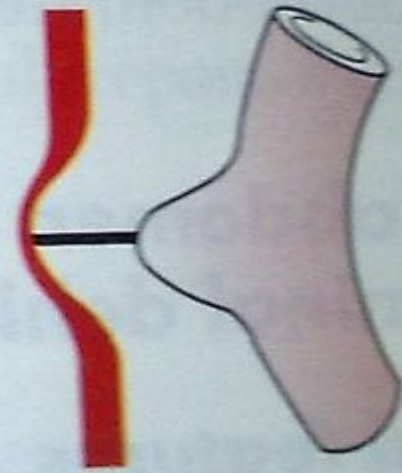When, as I  
will cure th



(b)



(d)



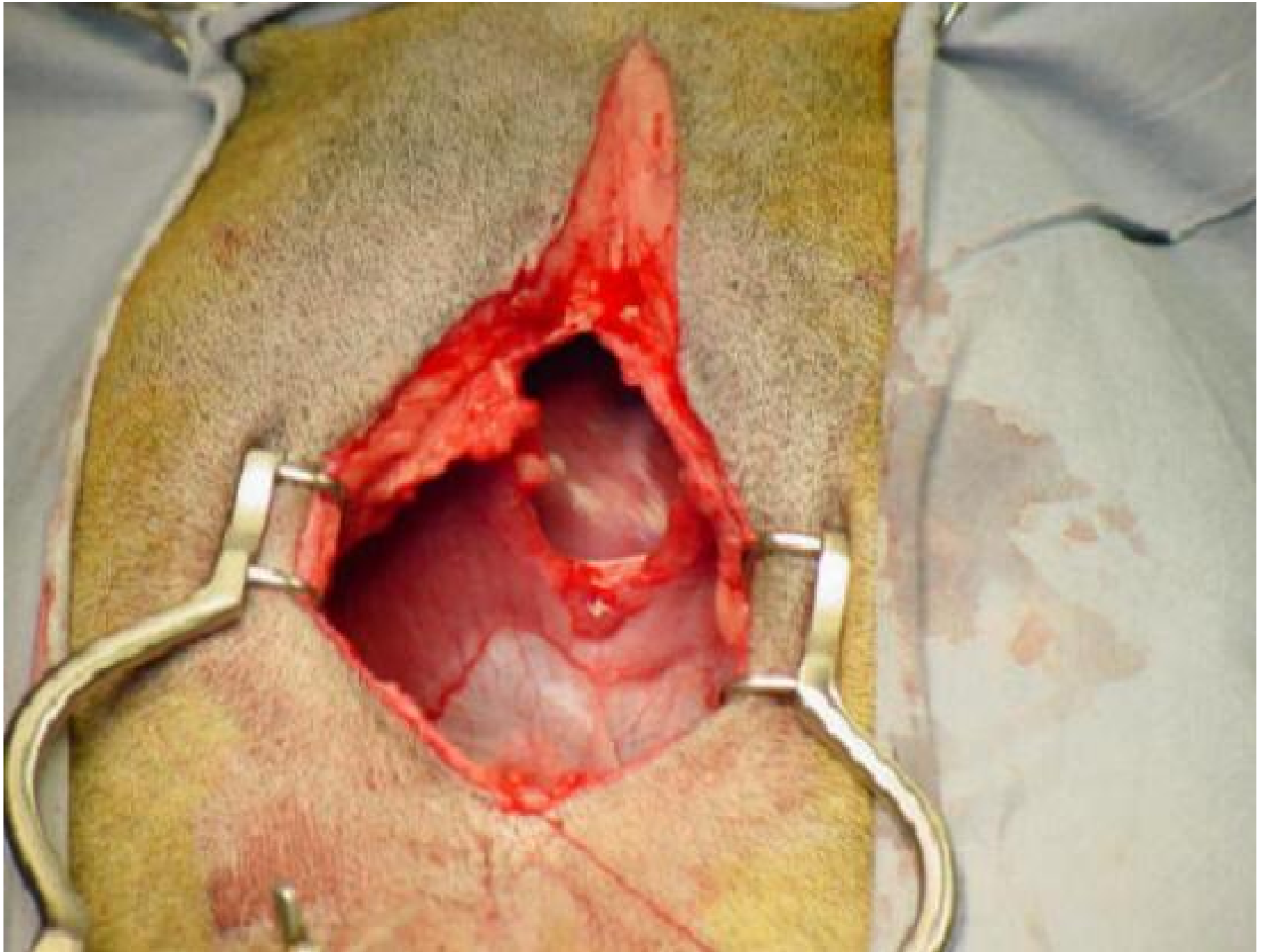
# Abdominal wall

- Burst abdomen ( abdominal dehiscence )  
the viscera extruded to out side due to burst of abdominal wall suturing
- Incisional hernia ;partial disruption of deeper layer the skin remain intact



# causes

- n Technique of wound closure
- n Factors related to incisions
- n Reasons for initial operation
- n Coughing, vomiting , distension
- n General condition (obesity ,jaundice ,malignant disease ,hypoprotinemia ,and anemia ,steroid ,pregnancy ,ascitis )





# Burst abdomen

---

- n Serosanguinous discharge ,the pathognomonic feature
- n Some time patient fell some thing giveway
- n Emergency operation

# Incisional hernia

- Aetiology
- Clinical features
- Treatment







