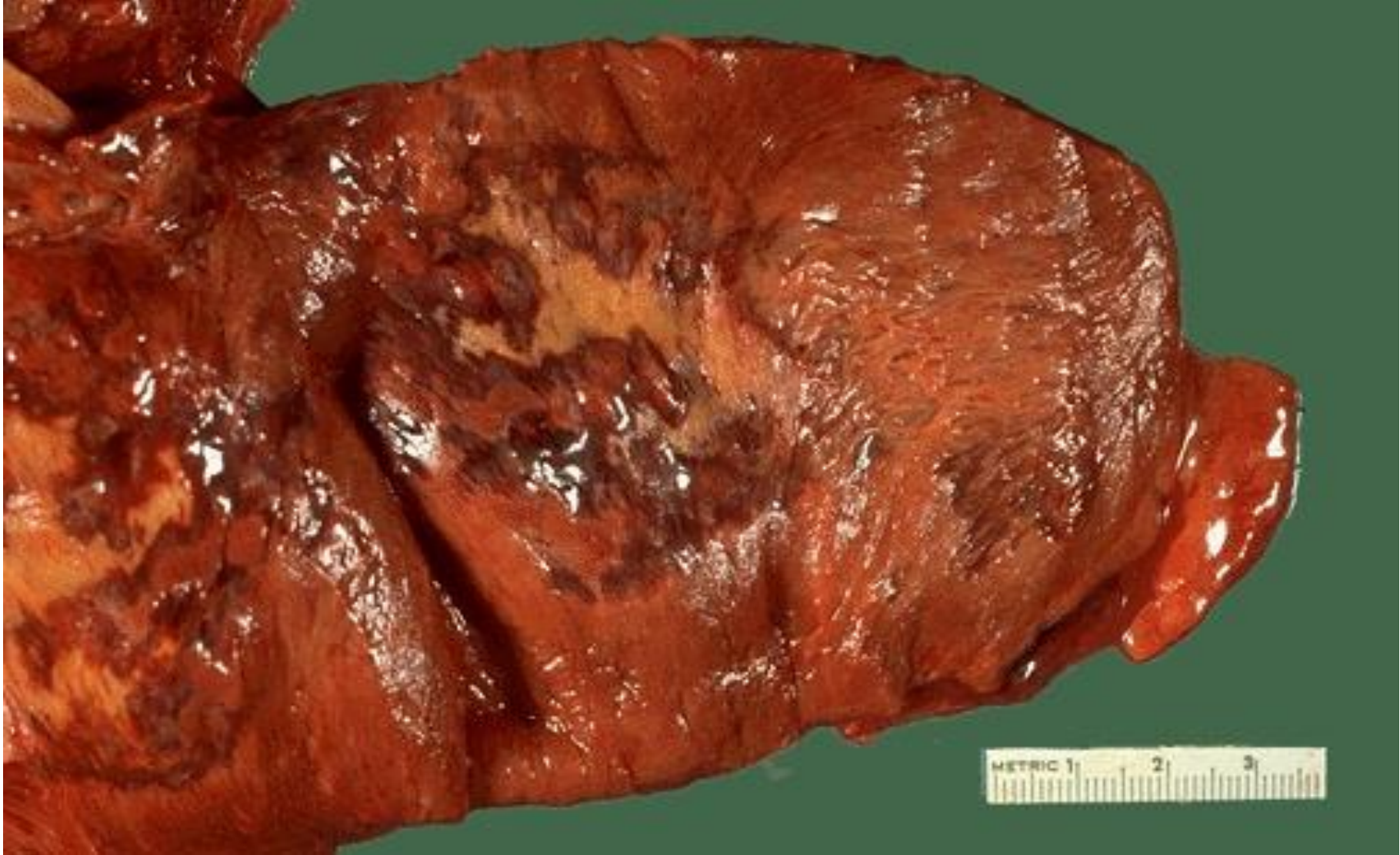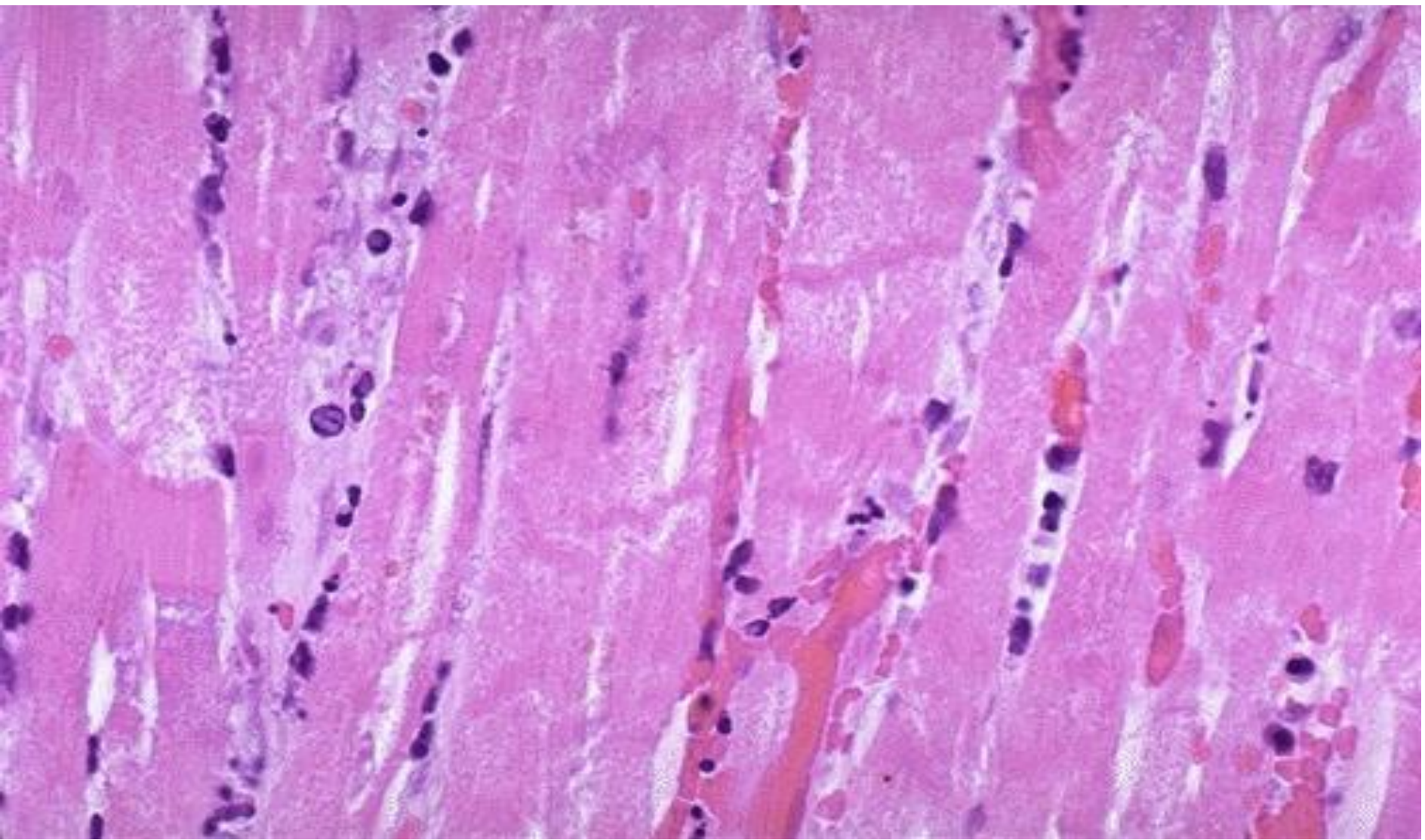
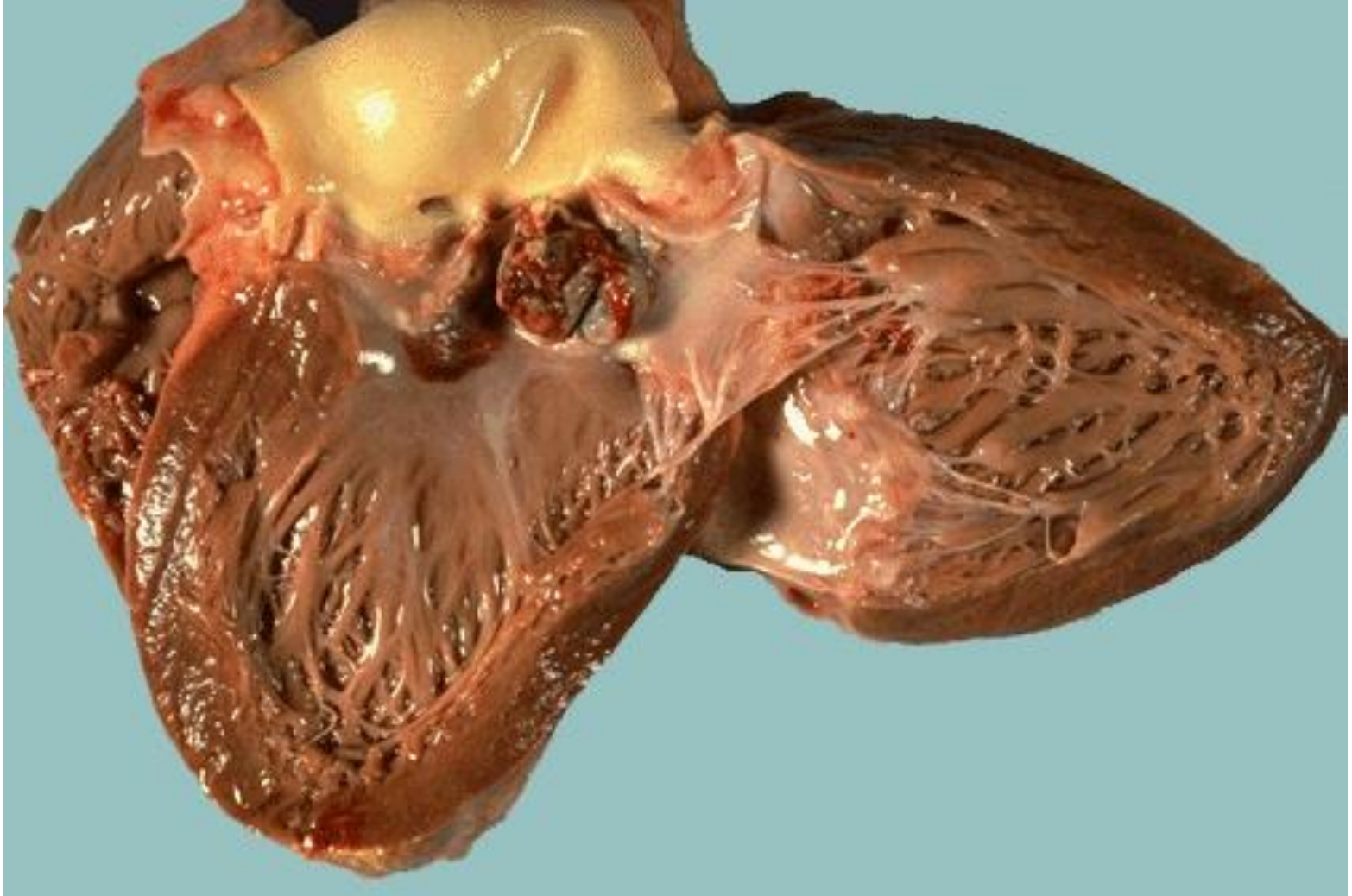




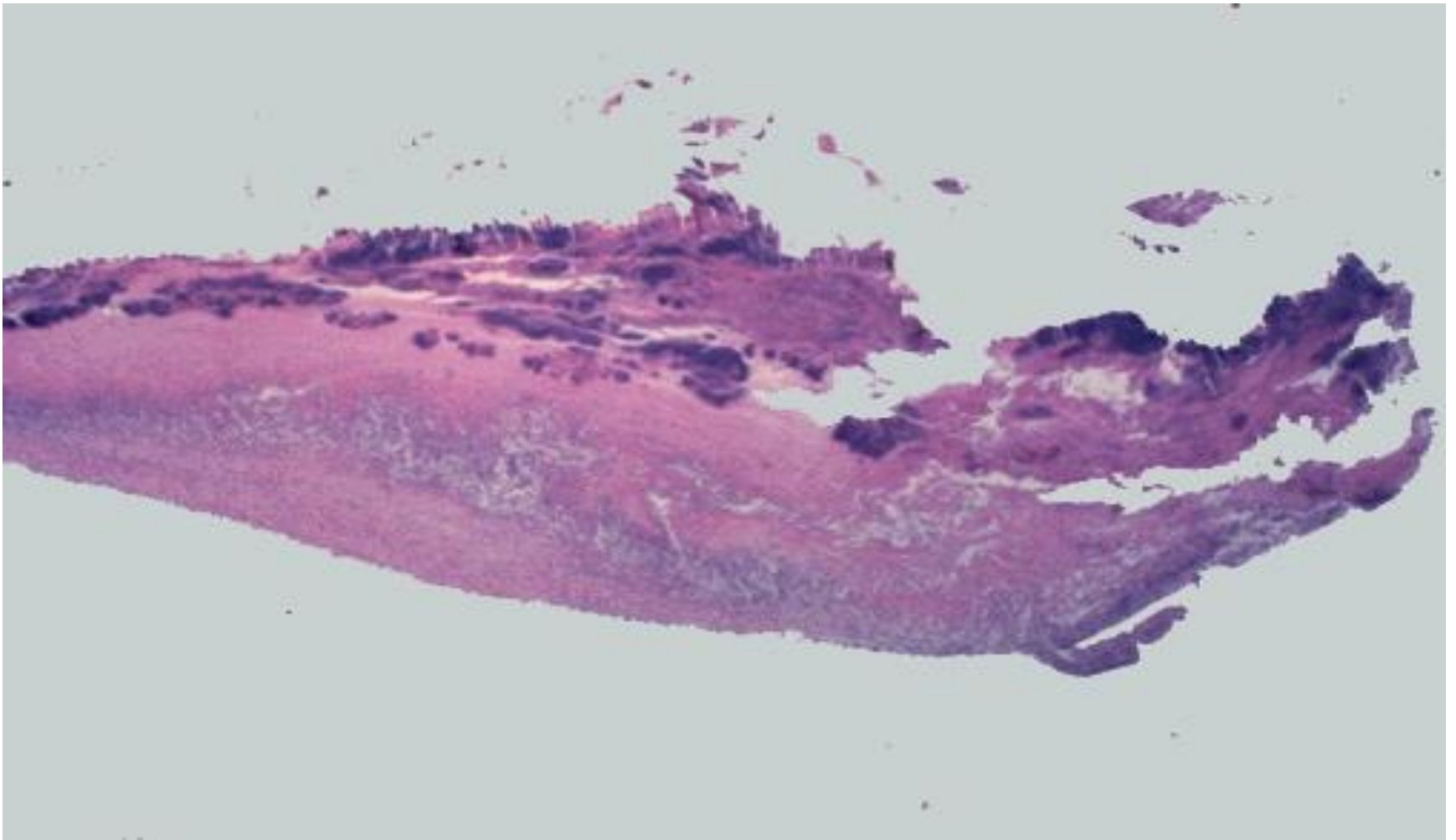
- A large recent myocardial infarction.



- 12 hours-one day old infarct



- This is infective endocarditis



- Microscopically, the valve in infective endocarditis